



PATIENT

Destiny Taverna

SPECIES

Feline

BREED

DSH

SEX

Female Spayed

AGE

13 years

WEIGHT

10.6lbs

INTERPRETED BY

Maggie Machen
Lamy, DVM
DACVIM (Cardiology)

IMAGING PERFORMED BY

Pamela Harrigan,
RDCS

HOSPITAL NAME

Mass Veterinary Services

REFERRING VET

Dr. Masloski

INVOICE

31783

DATE

7/11/23

PRESENTING CLINICAL SIGNS

History: Recheck echo. History HOCM, stable on prior echocardiogram. Presently, Destiny is doing fairly well. She has been hiding and more vocal since her feline housemates were recently euthanized. Otherwise, she does continue to eat well with normal activity level. On exam: NSR, grade II/VI murmur with PMI on sternum, PSS, lung fields clear, compressible thorax, mm pink, moist, CRT < 2. BP: 110 mmHg x 4. Current medications: 1) Atenolol 50mg/ml 0.125mls transdermal 2) Plavix/clopidogrel transdermal 18.75mg daily *No sedation for study. -Pertinent previous echo findings (1/11/23 MML): LA 1.5 cm; LA:Ao 1.6; IVS 0.44 cm; PW 0.69 cm; LVOT Vmax 1.1 m/s.

ECHOCARDIOGRAM FINDINGS

2D, m-mode, color flow and Doppler imaging is available.

Left ventricle: The LV diameter is normal with adequate myocardial function. The LV wall thicknesses are asymmetric with mild posterior wall hypertrophy. There is a diffusely hyperechoic endocardium consistent with fibrosis. False tendon. The papillary muscles are remodeled and hyperechoic. The endocardium appears remodeled.

Left atrium: The left atrium is mildly dilated with a horizontal component. No smoke or thrombi seen.

Mitral valve: The anterior leaflet of the mitral valve appears largely normal. Systolic anterior motion is seen on 2D imaging. Mild eccentric MR.

Aortic valve/Aorta: The aortic valve is normal in morphology and mobility. Normal aortic outflow velocity. Mild aortic insufficiency.

Right ventricle: Normal right ventricular diameter and morphology indicating no overt evidence of pulmonary arterial hypertension.

Right atrium: The right atrium is normal in dimension.

Tricuspid valve: The tricuspid valve appears normal with no tricuspid regurgitation.

Pulmonary valve/Pulmonary artery: The pulmonic valve is normal in morphology and mobility. No pulmonic insufficiency. Normal RVOT velocity.

Pericardium/other: No pericardial or pleural effusion noted. No obvious cardiac masses.

Heart rhythm: ECG reveals a sinus rhythm with an average HR of 188bpm.

2-Dimensional Measurements

Ao diam (cm)	1.0
LA diam (cm)	1.4
LA:Ao (Swe)	1.4
IVS thickness (cm)	0.52
LVID diastole (cm)	1.3
PW thickness (cm)	0.67
LVID systole (cm)	0.43
FS (%)	67

Doppler Measurements

PV Vmax (m/s)	0.6
AoV Vmax (m/s)	1.8
MR Vmax (m/s)	NA
TR Vmax (m/s)	NA
TR PG (mmHg)	NA

INTERPRETATION OF THE FINDINGS

Compared to the prior study, findings are similar. The LV wall thickness remains asymmetric and unchanged without obvious progression. A small aortic valve insufficiency is noted; however, the reported BP is low. The LA dimension remains mildly dilated, and no additional issues are identified.

Given these findings, continue medications as prescribed. Close monitoring for development of any clinical signs is recommended going forward.



PATIENT

Destiny Taverna

Prognosis is guarded long term.

SPECIES

Feline

RECOMMENDATIONS

- Continue Plavix and Atenolol as prescribed.
- Screening BP/T4 every 6 months.
- Elective anesthesia is not advised.
- Monitor for any clinical evidence of cardiac compromise, including respiratory changes and/or signs of a blood clot event (paralysis, neurologic changes, etc.).

BREED

DSH

PLAN

- Recommend recheck echocardiogram in 6-9 months to assess rate of progression, sooner if any issues arise in the interim.

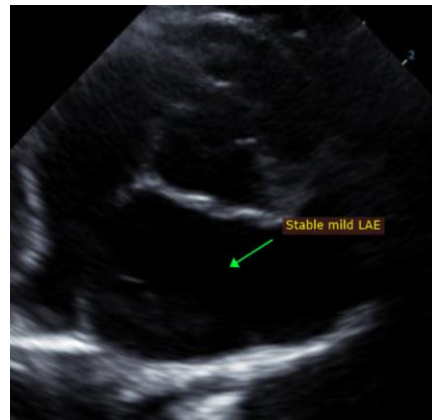SEX

Female Spayed

IMAGES

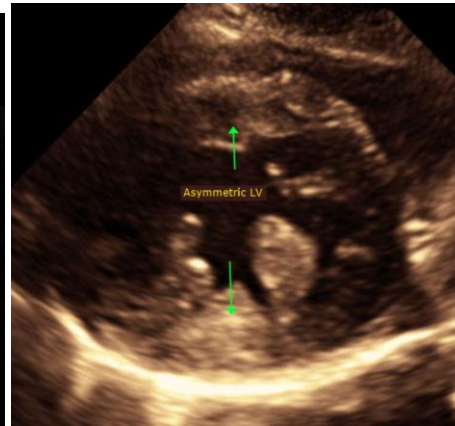
AGE

13 years



WEIGHT

10.6lbs



INTERPRETED BY

Maggie Machen
Lamy, DVM
DACVIM (Cardiology)

The information and recommendations provided are based on the images presented by the referring veterinarian. No evaluation can be communicated regarding pathology that was not visible in the image/video clips provided.

IMAGING PERFORMED BY

Pamela Harrigan,
RDCS

Thank you for this referral. This report was generated using transcription software, and minor dictation errors may be present. If the clinical or image interpretation does not parallel your findings or if I can be of any further assistance, please contact me.

HOSPITAL NAME

Mass Veterinary Services

Maggie Machen Lamy, DVM
Diplomate of the American College of Veterinary Internal Medicine (Cardiology)
info@sonopath.com

REFERRING VET

Dr. Masloski

Echocardiogram performed by:

Pamela Harrigan, RDCS
Pet Animal Ultrasound Service (4paus.com)

INVOICE

31783

DATE

7/11/23